



#9

Optimizing Immediate Obturator Fabrication Using a Digital-Analog Workflow

Jessica Poon, DMD*, Jason D. Lee, DDS, MMSc, Sungyong Ban, DDS, MMSc
Harvard School of Dental Medicine, Advanced Graduate Education in Prosthodontics



Abstract

A unique impression technique was employed for fabrication of an immediate obturator, involving the digital modification and 3D printing of the patient's existing ill-fitting obturator. This case demonstrates the integration of digital technology in the management of complex maxillofacial defects and the optimization of patient comfort during impression taking procedures.

Patient Presentation

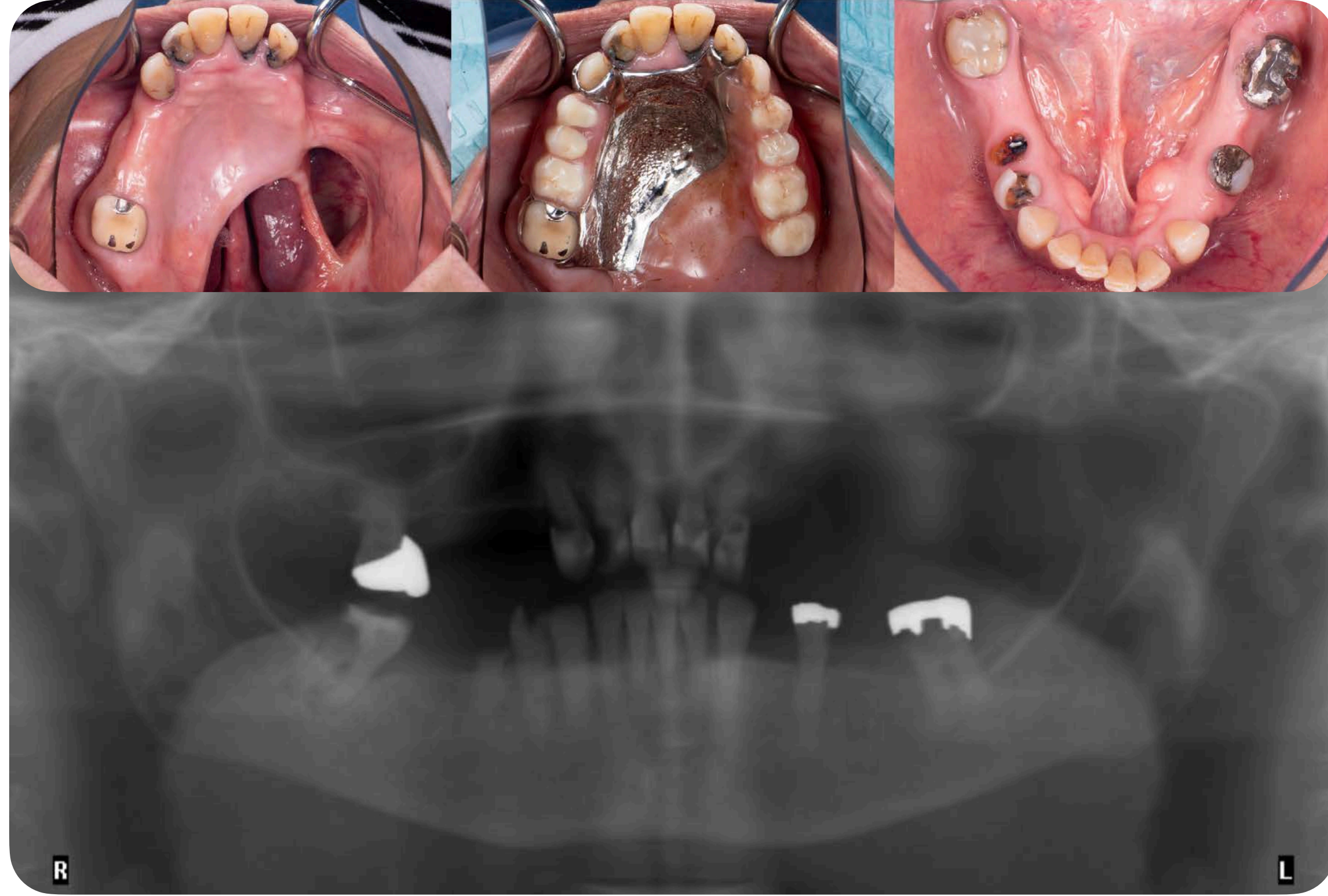
- 63-year-old female patient
- History of left palatal low-grade polymorphous adenocarcinoma in 2010 with partial maxillary resection
- Chief complaint: "I need my loose teeth taken out."
- Oral status: extensive caries, fractured/mobile teeth, mandibular large tori, and an ill-fitting existing maxillary partial denture obturator prosthesis

Treatment Plan

- Maxillary and mandibular extractions of hopeless dentition, mandibular tori removal, with delivery of immediate prostheses
- Future definitive maxillary complete obturator and mandibular complete denture after 6 months of post-extraction healing

Impression Technique Workflow

Pre-treatment



Visit 1 Lab scan of existing ill-fitting obturator and intraoral teeth scans

Lab Step 1 3D printed trays with 3 functions

1. Custom tray for capturing border extensions near teeth and defect region
2. Centric relation record through gothic arch tracing
3. Wax rim try in for edentulous spaces

Visit 2 Border Molding, Final Impressions, Wax Rim Try-in, CR Record, Face Scan

Lab Step 2 Merging files and fabricating immediate obturator and mandibular immediate denture

Visit 3 Extractions, tori removal, immediate obturator and mandibular immediate denture delivery

Clinical Significance
This case highlights the clinical value of using a digital-analog workflow to capture accurate impressions of a complex maxillary defect with minimal trauma to fragile dentition. The open-window design and multi-material impression technique enhanced precision and patient comfort. Digital workflows enabled the efficient fabrication of a well-adapted immediate obturator, streamlining care in maxillofacial prosthetic rehabilitation.

Acknowledgements
Dr. Wissanee Jia-Mahasap for clinical supervision and help with impressions.
Dr. Nalton Ferraro for clinical supervision for extractions and tori removal.

References

Alamri, O., Lee, S. J., Mwele, C., & Lee, J. D. (2025). An analog-digital hybrid technique for immediate dentures with idealized border extensions. *The Journal of prosthetic dentistry*, 133(2), 352-356. <https://doi.org/10.1016/j.prosdent.2023.03.032>
 Huang, C. C., Lee, S. J., Gallucci, G. O., & Lee, J. D. (2024). Digital trifunctional intraoral appliance for centric relation recording: A dental technique. *The Journal of prosthetic dentistry*, S0022-3913(24)00820-5. Advance online publication. <https://doi.org/10.1016/j.prosdent.2024.11.019>
 Koyama, S., Kato, H., Harata, T., & Sasaki, K. (2020). A workflow for fabricating a hollow obturator by using 3D digital technologies. *The Journal of prosthetic dentistry*, 123(4), 648-652. <https://doi.org/10.1016/j.prosdent.2019.05.020>